



PATIENT

Precious Downing

SPECIES

Canine

BREED

Labrador Retriever Mix

SEX

Female Spayed

AGE

9 years

WEIGHT

47lbs

INTERPRETED BY

Maggie Machen
Lamy, DVM
DACVIM (Cardiology)

IMAGING PERFORMED BY

Eduardo Rodriguez
III, RCS

HOSPITAL NAME

Norfolk County
Veterinary Service

REFERRING VET

Dr. Pietsch

INVOICE

30092

DATE

4/6/23

PRESENTING CLINICAL SIGNS

History: Recheck echo. History chronic valvular disease-Stage B1. Precious experiences exercise intolerance on walks. BP: 118, 120 mmHg. Current meds: 1) Rimadyl 100mg-1/2 BID, 2) Fluoxetine 20mg SID. *Sedated with Alfaxalone/Torbugesic.
-Pertinent previous echo findings (4/14/22 MML): LA 2.7 cm, LA:A0 1.2, LV 4.1 cm, normal LA/LV sizes, mild MR, trace TR (2.3 m/s)

ECHOCARDIOGRAM FINDINGS

2D, m-mode, color flow and Doppler imaging is available.

Left ventricle: The LV diameter is normal with adequate myocardial function. LV wall thicknesses are normal.

Left atrium: The left atrium is minimally enlarged.

Mitral valve: The mitral valve is mildly thickened with no prolapse into the left atrial lumen. Mild to moderate eccentric mitral regurgitation with a normal velocity.

Aortic valve/aorta: The aortic valve is normal in morphology and mobility. Normal aortic outflow velocity; laminar flow. No aortic insufficiency.

Right ventricle: Normal right ventricular diameter and morphology indicating no overt evidence of pulmonary arterial hypertension.

Right atrium: Normal RA dimension.

Tricuspid valve: The tricuspid valve appears normal with trace tricuspid regurgitation; normal velocity.

Pulmonic valve/pulmonary artery: The pulmonic valve is normal in morphology and mobility. No pulmonic insufficiency. Normal RVOT velocity; laminar flow.

Pericardium/other: No pericardial or pleural effusion noted. No obvious cardiac masses.

Heart rhythm: ECG reveals a sinus rhythm with an average HR of 80bpm.

2-Dimensional Measurements

Ao diam (cm)	2.2
LA diam (cm)	2.9
LA:Ao (Swe)	1.3
IVS thickness (cm)	1.0
LVID diastole (cm)	4.3
PW thickness (cm)	1.0
LVID systole (cm)	3.1
FS (%)	28

Doppler Measurements

PV Vmax (m/s)	0.85
AoV Vmax (m/s)	1.4
MR Vmax (m/s)	4.5
TR Vmax (m/s)	2.0
TR PG (mmHg)	16

INTERPRETATION OF THE FINDINGS

Chronic degenerative valve disease persists with evidence of slight progression. Quantitatively the MR is increased; however, the left heart dimensions are largely unchanged. The right heart remains normal, and no additional issues are identified.

Assessment of progression in the future will help predict long term prognosis, which is highly variable at this stage (B1).

RECOMMENDATIONS

- No cardiac medications are clearly indicated.
- Omega fatty acid supplementation and mild salt restriction may be of some long-term benefit.
- Anesthetic risk is considered mild if needed. Cardiac protective drug choices (opioid/benzodiazepine premedication, propofol or alfaxalone induction, isoflurane)



PATIENT

Precious Downing

SPECIES

Canine

BREED

Labrador Retriever Mix

SEX

Female Spayed

AGE

9 years

WEIGHT

47lbs

INTERPRETED BY

Maggie Machen Lamy, DVM
 DACVIM (Cardiology)

IMAGING PERFORMED BY

Eduardo Rodriguez III, RCS

HOSPITAL NAME

Norfolk County Veterinary Service

REFERRING VET

Dr. Pietsch

INVOICE

30092

DATE

4/6/23

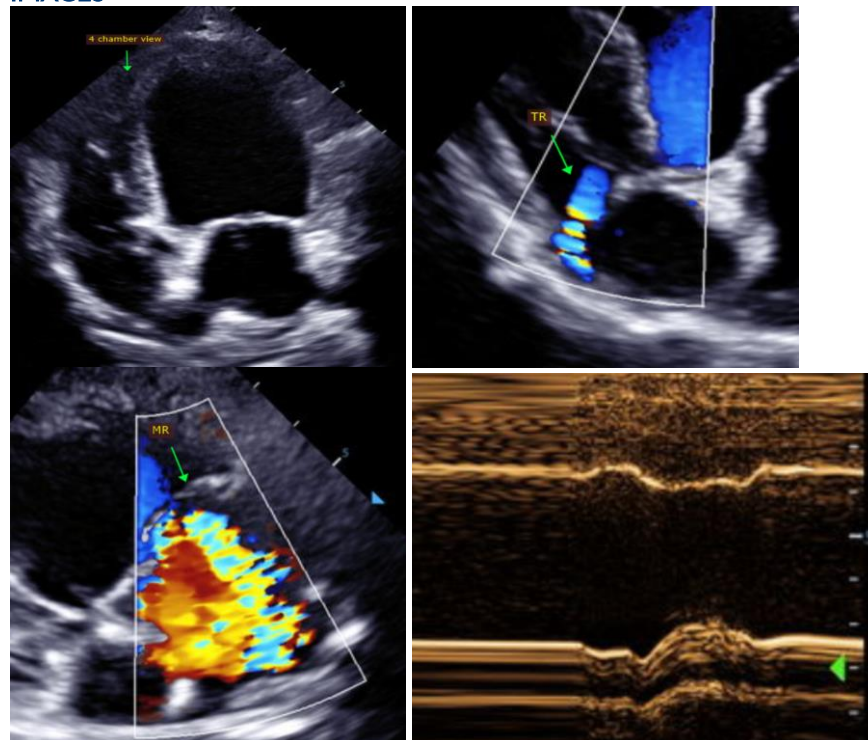
gas) are recommended. Pre-oxygenate for 5-10 minutes prior to induction. Monitor for arrhythmias, hypotension, and hypoxia both intra and post-operatively and intervene as necessary. Mild IV fluid restriction is recommended to avoid fluid overload. Avoid heart rate stimulating drugs such as atropine unless clinically indicated.

- Monitor for development of a cough, labored breathing, exercise intolerance or collapse episodes.

PLAN

- Recommend conservative monitoring with a recheck echocardiogram in 6 months, sooner if any development of clinical signs.

IMAGES



The information and recommendations provided are based on the images presented by the referring veterinarian. No evaluation can be communicated regarding pathology that was not visible in the image/video clips provided.

Thank you for this referral. This report was generated using transcription software, and minor dictation errors may be present. If the clinical or image interpretation does not parallel your findings or if I can be of any further assistance, please contact me.

Maggie Machen Lamy, DVM
 Diplomat of the American College of Veterinary Internal Medicine (Cardiology)
 info@sonopath.com

Echocardiogram performed by: Pamela Harrigan, RDCS
 Pet Animal Ultrasound Service (4paus.com)